

Guidewires Unintentionally Retained During Central Venous Catheterization

July 2013



UHC Safety Intelligence™
Patient Safety Organization

 **UHC Safety Intelligence™**
Applied Learning

Summary

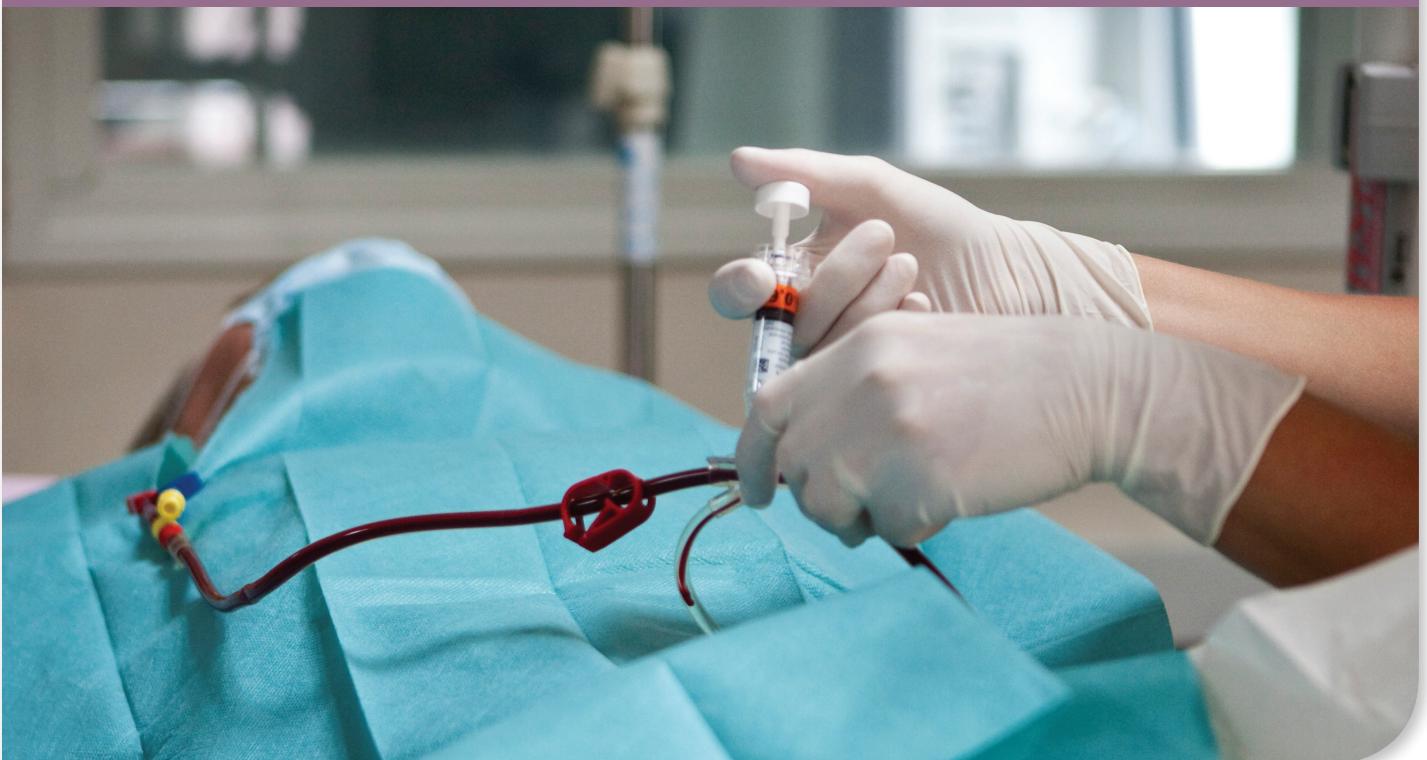Complications can occur during the insertion of a central venous catheter (CVC), including breakage/fracture of the guidewire, recognized loss of the wire during the procedure, and unrecognized failure to remove the wire during the procedure. This analysis highlights the findings from 42 incident reports on unintentionally retained CVC guidewires over a 5-year period from more than 40 organizations that participate in the UHC Safety Intelligence™ Patient Safety Organization (PSO). Reports of unintentionally retained CVC guidewires, their common causes, and system improvements to prevent these errors are discussed. Health care organizations and manufacturers of CVC insertion kits should take stronger action to prevent these unintended, serious adverse events.

Problem Statement

Between 5 and 6 million CVCs are inserted into patients every year to perform hemodialysis, to monitor central venous pressure, and to administer fluids, medications, and nutritional support that cannot be safely administered peripherally (Figure 1).¹ During CVC insertion, a number of mechanical complications can occur, including inadvertent cannulation of an artery, perforation of vessels or cardiac chambers, pneumothorax, hemothorax, catheter entrapment,

breakage/fracture of the guidewire, recognized loss of the wire during the procedure, and unrecognized failure to remove the wire during the procedure.²⁻¹⁵ The loss or retention of a guidewire can result in arrhythmia, vascular damage, thrombosis, embolism, infection, cardiac perforation, and tamponade.^{4,9,11,13} Complications related to the retention of a guidewire can be serious and have been reported to be fatal in up to 20% of cases.⁹

Figure 1. Central Venous Catheter



Background

The Seldinger (catheter-over-wire) technique is commonly used in CVC placement and is considered quite safe when properly applied. However, this technique is also associated with the occurrence of retained guidewires.^{2,4,10,13} The technique involves inserting an introducer needle into the vein, advancing the guidewire through the needle, removing the needle, and then advancing the catheter over the guidewire. Once the catheter is in place, the guidewire is removed. Its function is to establish venous access and direct the placement of the catheter. A J-tipped wire provides for smooth advancement and navigation around bends in vessels. The Seldinger technique reduces the risk of injury and air embolization and has a higher rate of successful catheterization than other methods.^{2,10,16}

A key reason that CVC guidewires are frequently retained or lost during insertion is that there is no mechanism in the design that allows the clinician to effectively secure the proximal end of the wire (the end that is outside of the patient) during insertion. The guidewire can be inadvertently advanced into the patient with the

catheter because the end the clinician holds is straight. Retention should be suspected if the wire or a piece of the wire is missing after the procedure is completed, if there is resistance to injection or poor venous back-flow from the distal lumen, or if an imaging test shows evidence of a guidewire.¹³ In most cases, the entire wire or fragment can be retrieved. The preferred method of doing so is through interventional radiology.^{9,11}

Poor technique during guidewire insertion can contribute to breakage or shearing of the wire. A common guidewire design is a straight central core wire that is wrapped with an outer layer of coiled wire. During insertion, the clinician may feel resistance and pull back on the wire. While being pulled back, the guidewire can catch or lock on the bevel of the introducer needle, particularly if the wire becomes bent or kinked.^{5,6} This locking of the wire with the needle can lead to breakage or shearing of the wire.⁶ In general, the guidewire should not be withdrawn through the needle because of the risk of shearing. The guidewire and the needle should be removed together as a unit.

Objective

The objective of this analysis was to review patient event reports on unintentionally retained CVC guidewires entered into the UHC Safety Intelligence™ database by more than 40 institutions participating in the UHC Safety Intelligence™ PSO. This analysis highlights the

reports of unintentionally retained CVC guidewires, describes the common causes of these events, and identifies system improvements aimed at preventing their occurrence.

Methods

A search was conducted of events entered in the UHC Safety Intelligence™ database by PSO members over a 5-year period from 2008 through 2012. The text field in which the reporter describes the event was searched for the words *central line*, *central venous catheter*, *CL*, *CVL*, *CVC*, and **wire**. In addition, all events entered into the UHC Safety Intelligence™ database under the new event type, “guidewire accidentally left in patient,” were

included in the review. Of the 137 events that met the search criteria, 95 were excluded because the events did not involve a retained guidewire. A total of 42 events that did involve a retained guidewire or fragment were included in this analysis. The annual rate of reported retained CVC guidewires per 1,000 staffed beds was calculated.

Findings

Trend in Reporting

Over the 5-year period, there were 42 events involving a retained CVC guidewire. Of those events, 31 (74%) involved an entire guidewire accidentally left in the patient, while the remaining 11 (26%) involved a fragment of a wire. The rate of reported CVC guidewire retention events per 1,000 staffed beds has increased in recent years (Figure 2). This increase could be related to UHC's updated taxonomy, which now includes the event type "guidewire accidentally left in patient," facilitating accurate identification of these events.

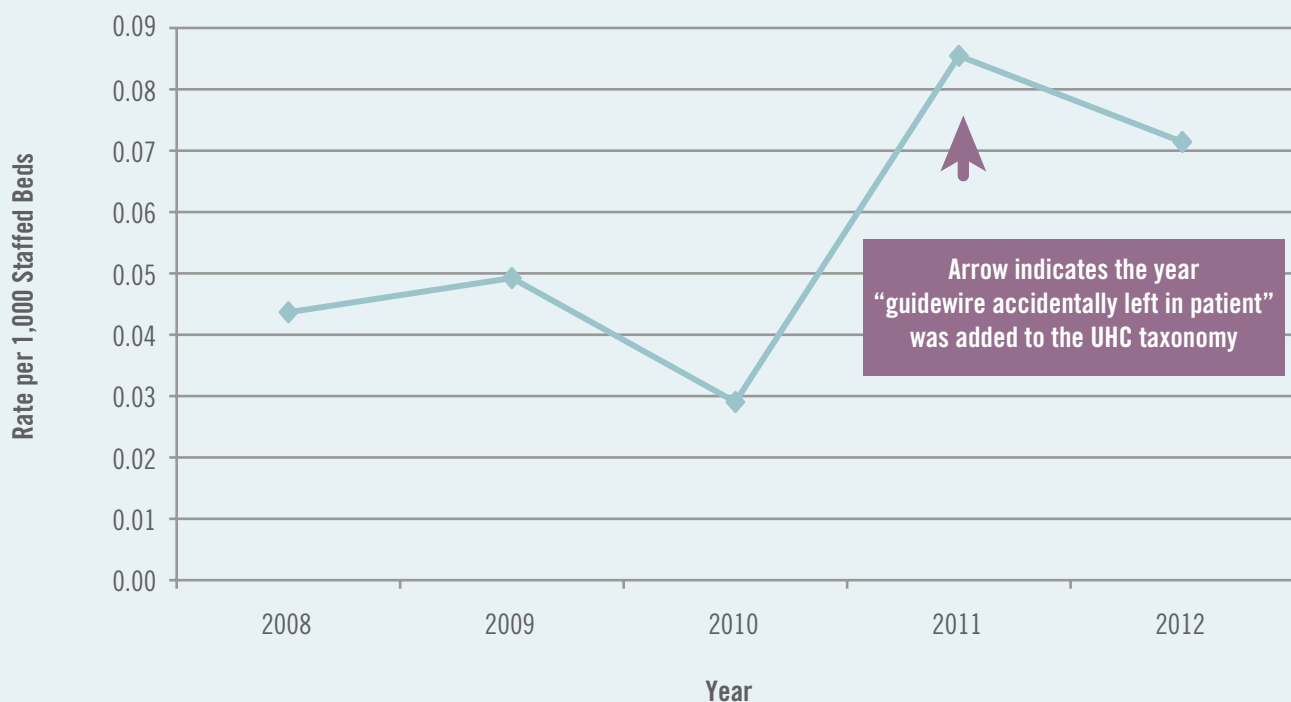
Discovery and Length of Retention

In one-third of the 42 cases (14), the missing or fractured guidewire was discovered during or at the end of the insertion procedure, and retrieval required interventional radiology. In 13 of the events, the retained guidewire was discovered through imaging tests performed for unrelated reasons. In 8 of the events, a

staff member discovered the wire in the port during assessment, administration of treatment, or change or discontinuation of the central line. In 4 cases, staff were alerted to the possibility of a retained wire when someone noticed that a checklist or procedural note did not indicate that the guidewire had been removed. The reviewer was not able to determine how the retained wire was discovered in 3 of the events.

In 14 events, the retained guidewire was discovered and removed on the day of insertion. In 12 cases, the guidewire was discovered and removed 1 to 6 days later but during the same hospitalization; in 3 cases, it was removed months to years later when discovered in the course of subsequent care. The organization that discovered the retained guidewire might not have been the same one that inserted the CVC. In the remaining cases, not enough information was provided in the report to determine how long the guidewire had been left in or whether it was a near-miss event (Table 1).

Figure 2. Trend in Reporting of Unintentionally Retained CVC Guidewires



CVC = central venous catheter.

Table 1. Retained CVC Guidewires: Discovery of Event and Length of Retention

Event Characteristics	Percentage of Events
How the Unintentionally Retained Guidewire Was Discovered	
Missing or fractured wire noted during or at the end of procedure	33
Discovered on imaging test that was obtained for other reasons; retained guidewire was not suspected	31
Staff discovered wire in port upon assessment, administration of treatment, or change or discontinuation of CVC	19
Documentation on checklist or procedural note did not indicate that guidewire had been removed	10
Unable to determine from description in event report	7
How Long the Guidewire Was Left In	
Removed on the same day as the CVC insertion	33
Removed up to 6 days later during the same hospitalization	29
Removed during a subsequent procedure or admission (months or years later)	7
Unable to determine from description in event report	31

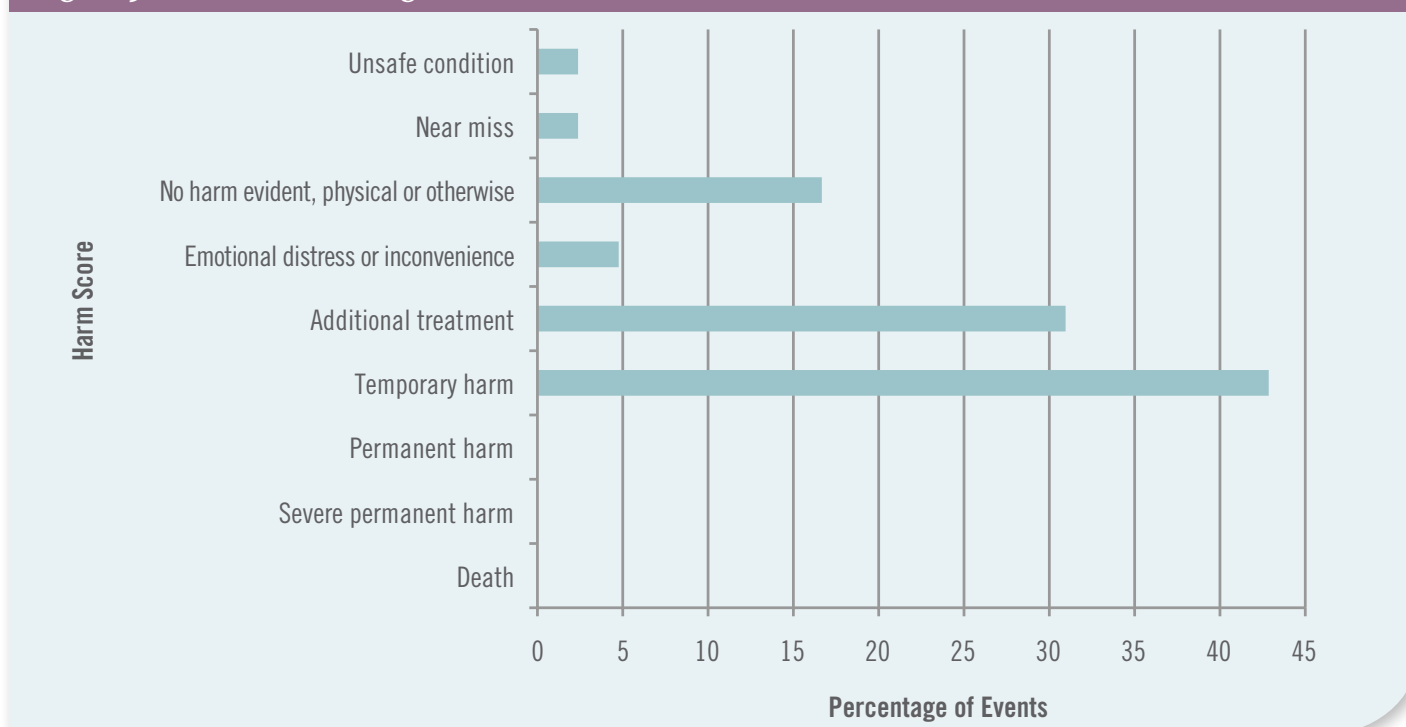
CVC = central venous catheter.

Harm Scores

Figure 3 displays the harm scores assigned to retained guidewire events using the Agency for Healthcare Research and Quality's Common Format Harm Scale

version 1.1. Although more than 40% of the events caused temporary harm, no events resulted in permanent harm or death.

Figure 3. Harm Scores Assigned to Retained CVC Guidewire Events

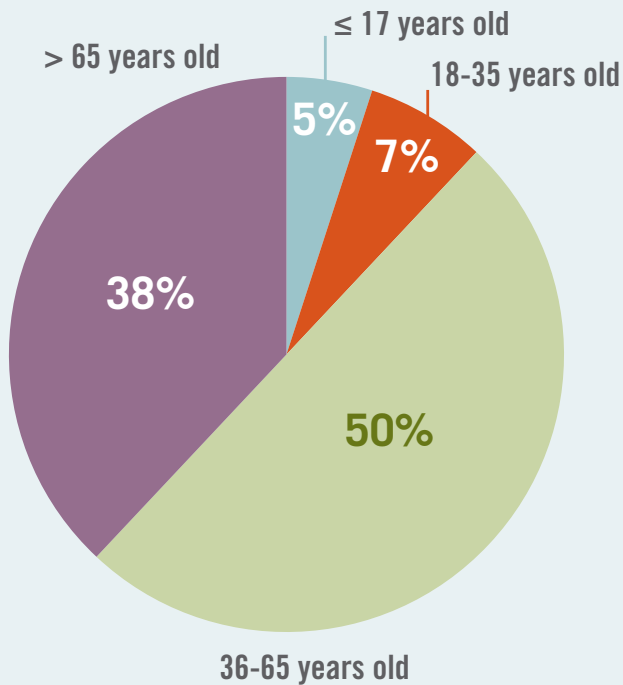


CVC = central venous catheter.

Age

Although the patients involved were mostly adults, all age groups were affected (Figure 4).

Figure 4. Retained CVC Guidewire by Patient Age Group



CVC = central venous catheter.

Location/Clinical Service

The locations that most commonly reported retained CVC guidewires were:

- Intensive care units (40%), including medical, surgical, cardiac, trauma, neurosurgery/neurology, and pediatric units
- Operating rooms (19%)
- Emergency departments (14%)

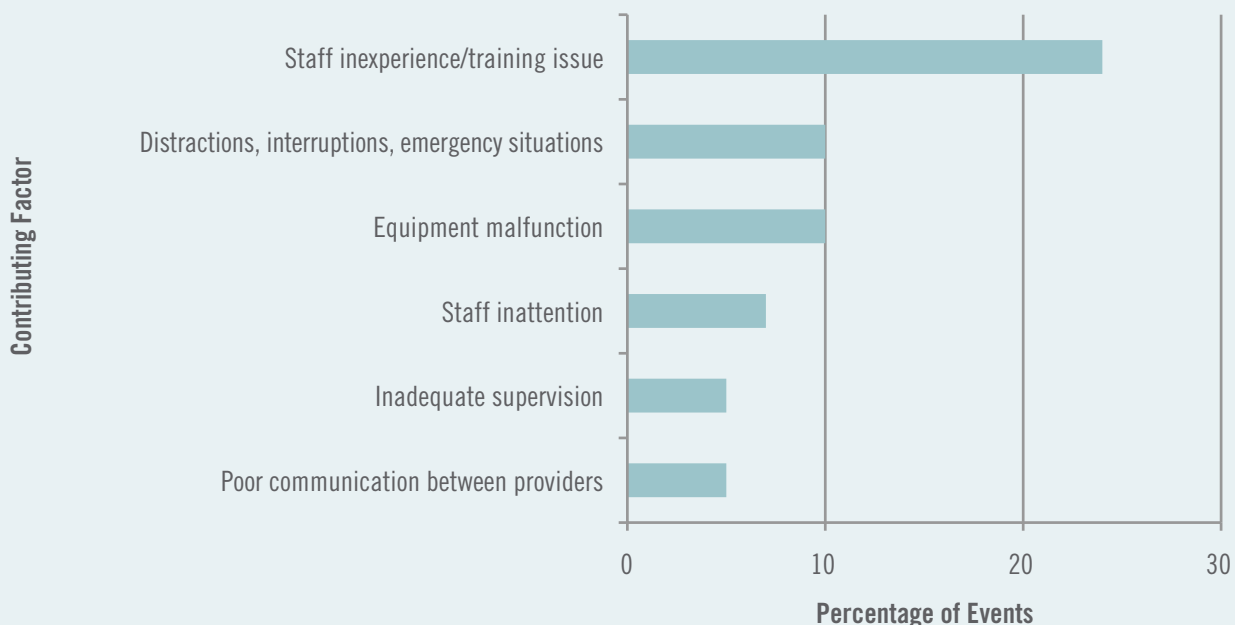
The clinical services most commonly involved in these events were:

- Critical care medicine (21%)
- General medicine (17%)
- Emergency medicine (12%)

Contributing Factors

The most common contributing factors identified by reviewing managers are displayed in Figure 5. Descriptions in the literature of factors contributing to retained guidewires are similar to those found in this study: inexperience in central venous cannulation or the Seldinger technique, distractions or emergencies, defective equipment, inattention during the procedure, inadequate supervision, communication issues, and guidewires that were not removed after being left

Figure 5. Most Common Factors Contributing to Retained CVC Guidewire Events^a



^a More than 1 factor could be selected for an event.
CVC = central venous catheter.

in intentionally for x-ray confirmation of the correct position.^{1-3,13,17} In addition, the narrative description of some events cited uncooperative or agitated behavior on the part of the patient (e.g., moving, bending, or grabbing) as a reason that a wire was lost or fractured during insertion.

The cause of guidewire breakage was not clear; materials were often sent back to the manufacturer for investigation with no further information provided. Broken or sheared guidewires may have been the result of poor technique by the clinician, often related to lack of experience. During insertion, the wire sometimes meets resistance and may become kinked. When the clinician pulls the wire back into the needle, the wire gets sheared off.^{5,6}

Preventive Strategies

Proper insertion technique is central to preventing guidewire errors; as long as the clinician maintains control of the proximal tip of the guidewire, it cannot be lost. But the 42 cases reported in this study suggest that the process of maintaining control of the guidewire throughout the procedure is susceptible to human error. Efforts to prevent the loss of the guidewire should include education and the development of a design for guidewires that prevents inadvertent loss and alerts the clinician when he or she is nearing the end of the wire.² Health care organizations should take stronger action to prevent retention and educate staff about its occurrence.

Strategies for preventing unintentionally retained CVC guidewires include the following:

- Increase education on the potential risk of losing the guidewire during insertion and the need to inspect it on removal to ensure that it is intact, particularly if resistance is encountered on withdrawal.¹⁷
- Educate clinicians that, in general, the guidewire should not be withdrawn through the needle. If the guidewire needs to be removed while the needle is still in place, the guidewire and needle should be withdrawn together as a unit. A bent guidewire should immediately be replaced with a new one.

Remedy/Corrective Actions

Many of the lost and retained CVC guidewire events in the UHC Safety Intelligence™ database were referred to interventional radiology for removal; interventional radiological methods are preferred for retrieving a lost or retained guidewire.^{9,11} The most common actions that managers identified to prevent lost and retained guidewires were education and training, discussion with the physician involved, revision of policies and procedures, and referral to medical leadership for follow-up. In some events related to breakage, the catheter and the guidewire were sent to the manufacturer for further investigation.

- Standardize the use of central line kits to avoid errors due to variations in kits.²
- Implement a central line checklist that includes confirmation of the removal of the guidewire and inspection of its integrity by the clinician and an assistant observer.^{2,10,17}
- Empower staff to remind the clinician to secure the end of the wire, to monitor for loss, and to stop the procedure if the wire becomes bent, broken, or lost.
- Check for the presence of foreign bodies on post-procedure imaging and identify the type of procedure performed on the imaging test requisition.²
- Explore alternative features in the design of CVC guidewires and kits:
 - Make the distal tip of the guidewire (the end inserted into the patient) a different color so that on its removal, staff can more easily identify breakage.
 - Design the guidewire so that it cannot advance into the catheter if the clinician lets go or loses sight of the wire. For example, ensure that the guidewire is long enough or develop a retention device that attaches to the proximal end of the wire (the end that is outside of the patient) to prevent it from advancing inside the catheter during placement.

- Make the proximal end of the guidewire a bright color so that it is visually prominent to the clinician, who should be able to see the end of the wire at all times during catheter insertion.²
- Include a reminder in the kit to remove the guidewire before accessing the suture needle (for example, a sticker over the needle).²

Although these strategies may not prevent all lost guidewires, they may lead to earlier identification of the problem so that retrieval can begin promptly.

Conclusion

Although unintentionally retained CVC guidewires have been seen as a rare occurrence, the body of literature on this topic is growing. Despite alerts, these events continue to occur, resulting in additional treatment and costs and potentially causing serious harm to patients. The 42 cases of unintentionally retained guidewires

in the UHC Safety Intelligence™ database most likely represent the tip of the iceberg, and greater attention by manufacturers and health care providers is warranted. Health care organizations and manufacturers of CVC insertion kits should take stronger action to prevent these unintended, serious adverse events.

Acknowledgments

Special thanks to T. Andrew Bowdle, MD, PhD, FASE, professor of anesthesiology and pharmaceuticals and director, Cardiothoracic Anesthesiology Simulation, Department of Anesthesiology, University of Washington;

and Bradford Winters, MD, PhD, associate professor, Armstrong Institute for Patient Safety and Quality, Johns Hopkins University, for their expert clinical contributions to this paper.

References

1. McGee DC, Gould MK. Preventing complications of central venous catheterization. *N Engl J Med*. 2003;348(12):1123-1133.
2. Lum TE, Fairbanks RJ, Pennington EC, Zwemer FL. Profiles in patient safety: misplaced femoral line guidewire and multiple failures to detect the foreign body on chest radiography. *Acad Emerg Med*. 2005;12(7):658-662. <http://www3.interscience.wiley.com/cgi-bin/fulltext/119821495/PDFSTART>. Accessed January 2013.
3. Kusminsky RE. Complications of central venous catheterization. *J Am Coll Surg*. 2007;204(4):681-696. <http://surgicalpatientsafety.facs.org/research/kusminsky.pdf>. Accessed January 2013.
4. Khasawneh FA, Smalligan RD. Guidewire-related complications during central venous catheter placement: a case report and review of the literature. *Case Rep Crit Care*. 2011. doi:10.1155/2011/287261.
5. Monaca E, Trojan S, Lynch J, Doehn M, Wappler F. Broken guidewire—a fault of design? *Can J Anaesth*. 2005;52(8):801-804.
6. Suzuki T, Ito K, Nishiyama J, Hasegawa K, Kanazawa M, Fukuyama H. Development of a safe guidewire. *J Anesth*. 2006;20(1):64-67.
7. Dhanani J, Senthuran S, Olivotto R, Boots RJ, Lipman J. The entrapped central venous catheter. *Br J Anaesth*. 2007;98(1):89-92.
8. Eisen LA, Narasimhan M, Berger JS, Mayo PH, Rosen MJ, Schneider RF. Mechanical complications of central venous catheters. *J Intensive Care Med*. 2006;21(1):40-46.
9. Bream PR Jr, Heffernan DS, Shukrallah B. Retrieval of a wire lost during central venous catheter replacement: a case report using a new technique for wire retrieval and a review of the literature. *Endovascular Today*. 2008;38-41. http://bmctoday.net/evtoday/pdfs/EVT0508_03.pdf. Accessed January 2013.
10. Lin C-Y, Hsu Y-J, Hong G-J, Tsai C-S, Lin S-H. Broken guidewire during subclavian venous catheterization. *Dial Transplantation*. 2006;35(8):536-537.
11. Kumar S, Eapen S, Vaid VN, Bhagwat AR. Lost guide wire during central venous cannulation and its surgical retrieval. *Indian J Surg*. 2006;68(1):33-34. <https://tspace.library.utoronto.ca/bitstream/1807/6379/1/is06007.pdf>. Accessed January 2013.
12. Guo H, Lee JD, Guo M. Guidewire loss: mishap or blunder? *Heart*. 2006;92(5):602.
13. Schummer W, Schummer C, Gaser E, Bartunek R. Loss of the guide wire: mishap or blunder? *Br J Anaesth*. 2002;88(1):144-146.
14. Pérez-Díez D, Salgado-Fernández J, Vázquez-González N, et al. Percutaneous retrieval of a lost guidewire that caused cardiac tamponade. *Circulation*. 2007;115(24):e629-e631. <http://www.circ.ahajournals.org/cgi/reprint/115/24/e629>. Accessed January 2013.
15. Phy MP, Neilson RW Jr. Guidewire complication with central line placement. *Hosp Physician*. 2004;40(6):41-43,50. http://www.turner-white.com/memberfile.php?PubCode=hp_jun04_line.pdf. Accessed January 2013.
16. Blitt CD, Carlson GL, Wright WA, Otto CW. J-wire versus straight wire for central venous system cannulation via the external jugular vein. *Anesth Analg*. 1982;61(6):536-537.
17. Safety alert 002/09: guidewire alert: reducing incidents involving guidewire insertion techniques. NSW Health Web site. <http://www.health.nsw.gov.au/resources/quality/sabs/pdf/sa20090616.pdf>. Published June 16, 2009. Accessed January 2013.

155 North Wacker Drive
Chicago, Illinois 60606

uhc.edu

© 2013 UHC. All rights reserved. The reproduction or use of this document in any form or in any information storage and retrieval system is forbidden without the express, written permission of UHC.

7/13

